

A. D. Jatene \*  
V. F. Fontes \*  
P. P. Paulista \*  
L. C. B. de Souza \*  
F. Neger \*  
M. Galantier \*  
J. E. M. R. Souza \*

SUCCESSFUL ANATOMIC CORRECTION  
OF TRANSPOSITION OF THE GREAT  
VESSELS. A PRELIMINARY REPORT.

The authors present a new approach for anatomical correction of transposition of the great vessels. The two coronaries with a piece of aortic wall are transposed to the posterior artery. The two aortic openings are closed with a patch. The aorta and pulmonary artery are transected, contraposed and then anastomosed. The interventricular septal defect was closed through a right ventriculotomy with a dacron patch. A 40-day-old white male infant with 3,700 g was operated on with deep hypothermia and total circulatory arrest and made an uneventful recovery. The hemodynamic study 20 days after surgery showed the complete correction of the malformation. At 50 days after surgery, he weighed 5,500 g, without cyanosis and in good conditions.

The ideal operation for transposition of the great vessels must be the one made at the arterial level. The major technical difficulty in this approach has been the transfer of the coronary arteries. Some attempts at anatomic correction have been altogether unsuccessful<sup>1,2,3,4,5</sup>. Recently anatomopathological and experimental studies have been reported on this subject<sup>6,7,8</sup>.

To our knowledge this is the first successful report of total correction of transposition of the great vessels at the arterial level.

#### CASE REPORT

A 40-day-old white male infant was first seen on May 6, 1975. He had been cyanotic 10 days after birth. At that time he developed cough and tachypnea. With 40 days he developed again cough, tachypnea and congestive heart failure with increasing cyanosis. He was treated with digitalis, diuretics and antibiotics. On examination, the edge of the liver was 3 cm below the right costal margin. There was a grade 2 systolic murmur at the mesocardium. A roentgenogram (Figure 1A) revealed an enlarged heart

From the Department of Surgery, Institute of Cardiology of the State of São Paulo, Brazil. Address for reprints: Dr. Adib D. Jatene. C. Postal 215. São Paulo, SP, Brasil.

and a considerably increased vasculature of the lungs. Data obtained at cardiac catheterization (Table 1) and cineangiography (Figure 1B) established the diagnosis of transposition of the great vessels with a large ventricular septal defect. Because of the pulmonary hypertension and heart failure it was considered necessary to operate the patient on, at that time.

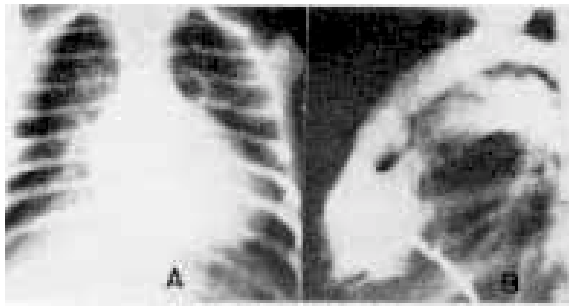


Fig. 1 - A: Preoperative roentgenogram. B: preoperative cineangiogram.

TABLE I

- CARDIAC CATHETERIZATION DATA\* -  
PREOPERATIVE

	Pressure (mm Hg)	Oximetry (%)
SVC	8 (m)	77
RA	8 (m)	79
RV	90/13	88
Ao	90/55	88
PA	75/35	98
LA	15 (m)	98
LV	90/12	97

\*Under general anesthesia

The operative procedure was made on May 8, 1975, through a median sternotomy.

The ascending aorta (presently anterior), the pulmonary trunk (presently posterior) and the initial portion of the coronary arteries were completely dissected. Two stitches using a

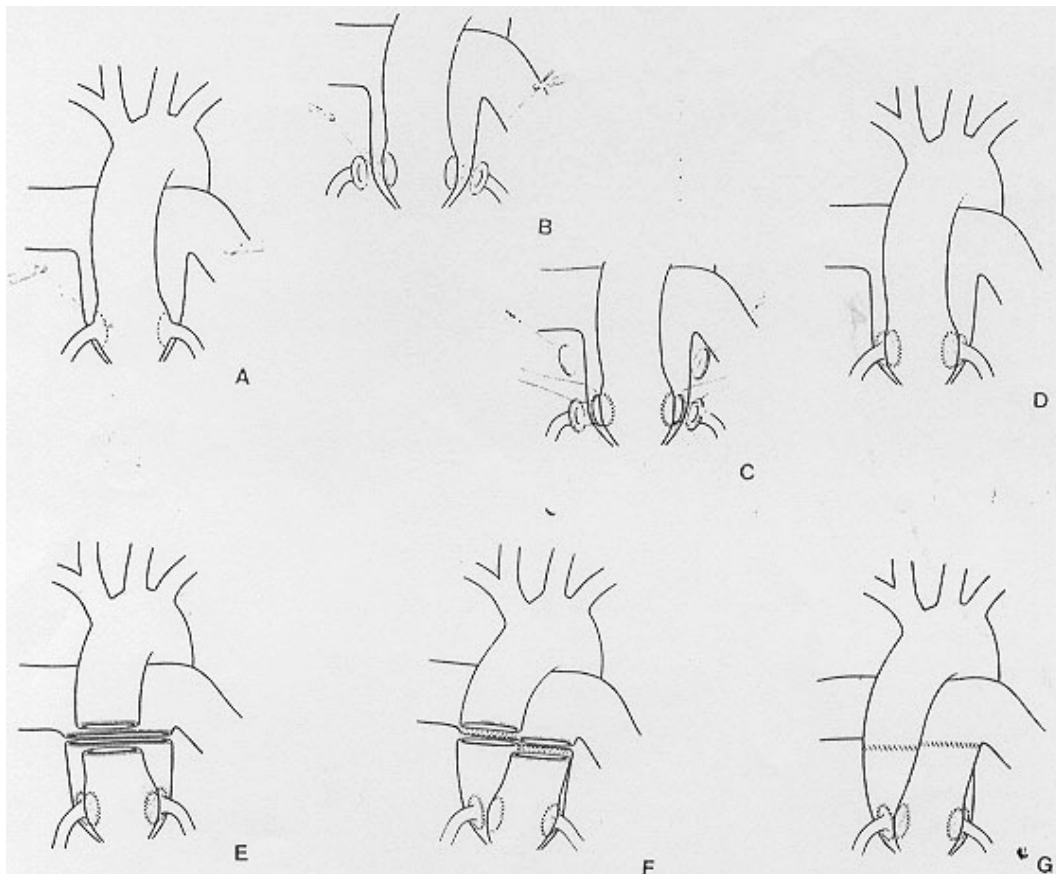


Fig. 2 - Schematic drawing of the operative technique.

6.0 prolene suture indicate the two places in the anterior wall of the pulmonary artery where the coronary arteries will be sutured (Figure 2A). After heart lung by-pass and deep 15° C hypothermia total cardiac arrest was instituted. The two coronary arteries were excised with a piece of the aortic wall (Figure 2B). The openings in the aortic wall were closed with a running suture using a piece of homologous dura mater preserved in glycerol<sup>9</sup>. Guided by the two stitches previously placed, two similar pieces of the posterior artery (presently pulmonary) were resected (Figure 2C). Two anastomoses were then performed with continuous 6.0 prolene suture implanting the coronary arteries in their new sites (Figure 2D). The next step was the trans-section of the ascending aorta and pulmonary artery trunk (Figure 2E). The difference in diameter was obviated by two sutures in the distal and proximal stumps of the pulmonary artery. These two sutures make equal the diameter of the vessels which are going to be contraposed and reanastomosed (Figure 1F). The distal and of the anterior artery is sutured with the proximal and of the posterior artery which now has the coronary arteries. The distal and of the pulmonary artery is sutured with the proximal and of the anterior artery, now without coronary arteries. Because the right ventricle is not systemic anymore but a pulmonary ventricle, the interventricular septal defect was treated through a right ventriculotomy. A dacron patch was inserted with interrupted mersilene 3.0 sutures.

The postoperative course was uneventful. Twenty days after surgery a right and left heart catheterization was performed. The cineangiographic aspect is shown in Figure 3. We can see the complete correction, and the coronary arteries at their new sites. The pulmonary pressure was 25/13 mm Hg and the pressure in the right ventricle was 60/10 mm Hg. The mean pressure in the left and right atriums was 10 and 6 mm Hg, respectively. The infant was discharged 3 weeks after the operation in good con-

ditions. Fifty days after surgery he was re-evaluated being considered in very good conditions without any cyanosis. He weighs presently 5,500 g against 3,700 g at the time of the surgery.

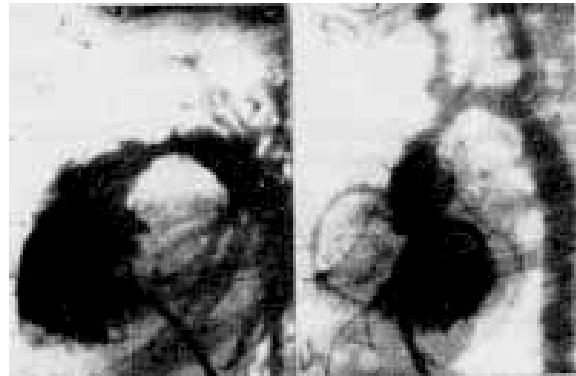

Fig. 3 - Postoperative cineangiogram.

#### COMMENT

The idea of retransposing the great vessels in patients with transposition of the great vessels is not new. The attempts of Bailey and associates<sup>2</sup>, Kay and associates<sup>3</sup>, and the proposal of Björk<sup>10</sup> leave the coronary arteries in the pulmonary artery. With the Mustard and associates technique<sup>1</sup> the left coronary artery was taken together with the aorta but the right one remained in the pulmonary artery. Senning<sup>4</sup> was the first who completely corrected the transposition, but his technique is very difficult to be used. Idriss and associates<sup>5</sup>, in 1961, developed an interesting technique but the ring of the aorta with the two coronaries is difficult to obtain and the anastomoses are all made very near the valve level. At this time all the patients in whom the techniques above were tried have died at the operating room or shortly after. Since that time we have not found new attempts in literature. The papers of Anagnostopoulos<sup>6</sup>, Anagnostopoulos and associates<sup>7</sup>, and Balderman and associates<sup>8</sup> have interesting ideas but no clinical experience. We designed our technique based on our experience on aorto-coronary bypasses<sup>11</sup> and it sounded to us as technically feasible. The two major arguments are: first, the coronary arteries are excised with

a piece of the aortic wall, so we have no problems with suture and future stenosis; second, the transections of the great vessels are made far from the valves making the anastomoses easier to do and to correct if any leak is observed. It also permits the adjustment of the sizes of the two vessels. We believe this technique is reproducible by most of the cardiovascular surgeons. We still believe at the present time that the transposition of the great vessels with an intact ventricular septum must be corrected by the Mustard operation<sup>12</sup>. We think that the left ventricle in this situation, being exposed to a low pressure regimen, perhaps will not be able to sustain the load of the systemic pressure. The same is true for cases with pulmonary stenosis. The Rastelli operation<sup>13</sup> should be the procedure of choice for this group of patients. But for transposition of the great vessels with ventricular septal defect with pulmonary hypertension the technique reported here will be the best approach.

### RESUMO

Os autores apresentam uma nova técnica para correção anatômica da transposição dos grandes vasos. As duas coronárias com um fragmento de parede da aorta são transpostas para a artéria posterior. A aorta e a artéria pulmonar são seccionadas transversalmente, contrapostas e anastomosadas. A comunicação interventricular é fechada com retalho de tecido de dacron.

A operação foi realizada em uma criança com 40 dias de idade e 3.700 gramas de peso, utilizando-se hipotermia profunda e parada circulatória total. No período pós-operatório, não foram observadas complicações. A reavaliação hemodinâmica feita 20 dias após a operação demonstrou correção da deformidade. Aos 50 dias de pós-operatório, a criança se apresentava em muito boas condições, sem cianose e pesando 5.500 gramas.

### REFERENCES

1. Mustard, W. T.; Chute, A. L.; Keith, J. D.; Sirek, A.; Rowe, R. D.; Vlad, P. - A surgical approach to transposition of great vessels with extracorporeal circuit. *Surgery*, 36: 39, July 1954.
2. Bailey, C. P.; Cookson, B. A.; Downing, D. F.; Neptune, W. B. - Cardiac surgery under hypothermia. *J. Thorac. Surg.* 27: 73, 1954.
3. Kay, E. B.; Cross, F. S. - Surgical treatment of transposition of the great vessels. *Surgery*, 38: 712, Oct. 1955.
4. Senning, A. - Surgical correction of transposition of the great vessels. *Surgery*, 45: 966, June 1959.
5. Idriss, F. S.; Goldstein, I. R.; Grana, L.; French, D.; Potts, W. J. - A new technic for complete correction of transposition of the great vessels. *Circulation*, 24: 5, July 1961.
6. Anagnostopoulos, C. E. - A proposed new technique for correction of transposition of the great arteries. *Ann. Thorac. Surg.* 15: 565, June 1973.
7. Anagnostopoulos, C. E.; Athanasuleas, C. L.; Arcilla, R. A. - Toward a rational operation for transposition of the great arteries. *Ann. Thorac. Surg.* 16: 458, Nov. 1973.
8. Balderman, S. C.; Athanasuleas, C. L.; Anagnostopoulos, C. E. - Coronary artery anatomy in transposition of the great vessels in relation to anatomic surgical correction. *J. Thorac. Cardiovasc. Surg.* 67: 208, Feb. 1974.
9. Pigossi, N. - Implantação de dura-mater homogênea conservada em glicerina: estudo experimental em cães. *Rev. Hosp. Clin. Fac. Med. S. Paulo*, 22: 204, 1967.
10. Björk, V. O.; Bouckaert, L. - Complete transposition of the aorta and the pulmonary artery: an experimental study of the surgical possibilities for its treatment. *J. Thorac. Surg.* 28: 632, 1954.
11. Jatene, A. D.; Sousa, J. E. M. R.; Paulista, P. P.; Magalhães, H. M.; Souza, L. C. B.; Fontes, V. F.; Piegas, L. S.; Soares, M. Z. - Le pontage aorto-coronaire de veine saphène: a propos de 671 cas. *Coeur*, 3: 607, Nov./Déc. 1972.
12. Mustard, W. T. - Successful two-stage correction of transposition of the great vessels. *Surgery*, 55: 469, 1964.
13. Rastelli, G. C.; MacGoom, D. C.; Wallace, R. B. - Anatomic correction of transposition of the great arteries with ventricular septal defect and subpulmonary stenosis. *J. Thorac. Cardiovasc. Surg.* 58: 545, 1969.