J THORAC CARDIOVASC SURG 78:402-412, 1979

Patch enlargement of the aortic valve ring by extending the aortic incision into the anterior mitral leaflet

New operative technique

This communication describes a new surgical procedure of enlarging the narrow aortic valve ring by extending the aortic incision through the fibrous origin of the aortic leaflet of the mitral valve into this leaflet. A fusiform patch is sutured to the V-shaped defect in the aortic leaflet of the mitral valve and in the aortic anulus. This procedure permits the replacement of the aortic valve by a suitable prosthesis. Between June of 1976 and February of 1978, eight patients underwent this surgical procedure. At the time of operation the patients were between 8 and 50 years old. The estimated enlargement of the aortic root ranged from 10 to 25 mm. The operative technique is described, peculiarities of this method are discussed, and the results are reported. Six to 27 months following operation, the clinical condition of six patients is good. Four patients show no impairment of mitral valve function. In one case, preoperatively diagnosed mitral incompetence persists. In another patient the pericardial patch broke from the aortic leaflet of the mitral valve, so that the valve had to be replaced on the fourth postoperative day. One patient died of myocardial necrosis because of insufficient myocardial protection during operation. One child with acute aortic insufficiency caused by staphylococcal endocarditis and congestive heart failure died of septicemia 3 months postoperatively. Mitral incompetence was not detectable in this child.

S. Manouguian, M.D.,* *Göttingen, West Germany,* and W. Seybold-Epting, M.D.,** *Tübingen, West Germany*

Aortic valve replacement in the presence of a normal or large aortic root can be accomplished with ease and safety. The presence of a hypoplastic, small aortic anulus, however, creates a difficult technical problem because both mechanical prostheses and stent-mounted tissue valves have significant resting gradients in the smaller sizes.[1-3] Whenever possible, the smaller prostheses of any type should be avoided.

Several significant findings, some of recent origin, allow a new operative technique of enlarging the narrow aortic anulus and replacing the aortic valve by a suitable prosthesis. First, there is the anatomic continuity between the posterolateral part of the aortic root and the aortic leaflet of the mitral valve.[4] Second, x-ray cinematographic studies of the section of the left fibrous anulus between the left and right fibrous trigones show that this section on which the posterolateral part of the aortic root rests and to which the anterior mitral leaflet is attached exhibitis no changes during cardiac action.[5] Furthermore, the anterior mitral leaflet is functionally wholly passive.[6] Finally, our own experimental results[7, 8] indicate that no impairment of mitral valve function results from the patch enlargement technique described in this report.

From the Department of Thoracic and Cardiovascular Surgery (Director: Prof. Dr. med. J. Koncz), Georg-August-University, Göttingen, West Germany, and the Department of Thoracic and Cardiovascular Surgery (Director: Prof. Dr. med. H. E. Hoffmeister), Eberhard-Karls-University, Tubingen, West Germany.

Supported by Deutsche Forschungsgemeinschaft SFB 89 Kardiologie, Göttingen, West Germany.

Received for publication Feb. 12, 1979.

Accepted for publication March 20, 1979.

Address for reprints: Priv.-Doz. Dr. S. Manouguian, Chirurgische Universitätsklinik der Ruhruniversität Bochum (Direktor: Prof. Dr. med. W. Brinkmann), Marienhospital Herne 1, Hölkeskampring 40, D-4690 Herne 1, West Germany.

*Assistant Professor of Thoracic and Cardiovascular Surgery, Georg-August-University.

**Assistant Professor of Thoracic and Cardiovascular Surgery, Eberhard-Karls-University.

0022-5223/79/090402+11$01.10/0 © 1979 The C. V. Mosby Co.

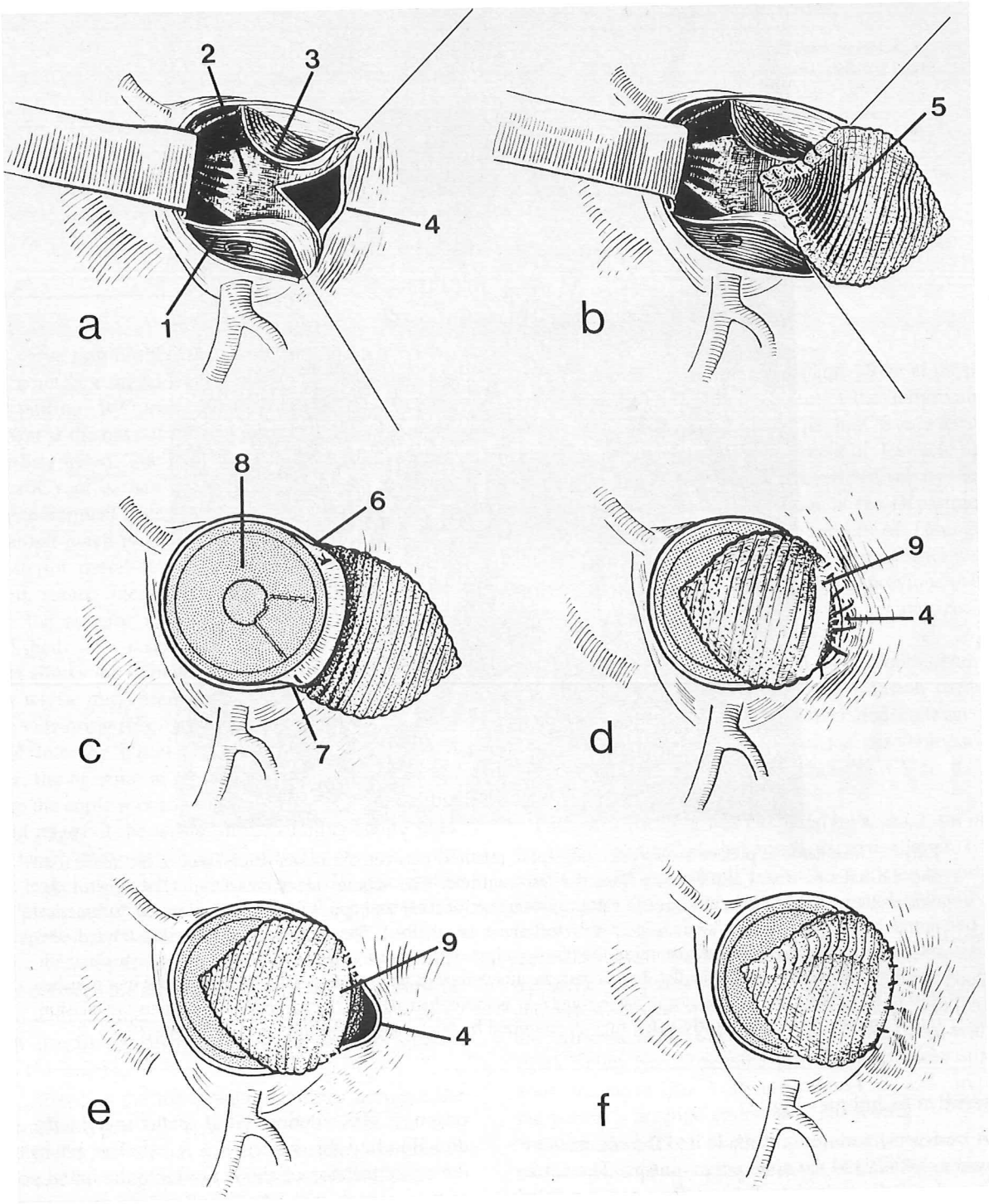

Fig. 1. Operative technique. *1*, Left semilunar cusp. *2*, Anterior mitral leaflet. *3*, Noncoronary semilunar cusp. *4*, Left atrial wall. *5*, Patch. *6-7*, Enlargement of the aortic valve ring. *8*, Aortic valve prosthesis. *9*, Sewing ring of the prosthesis.

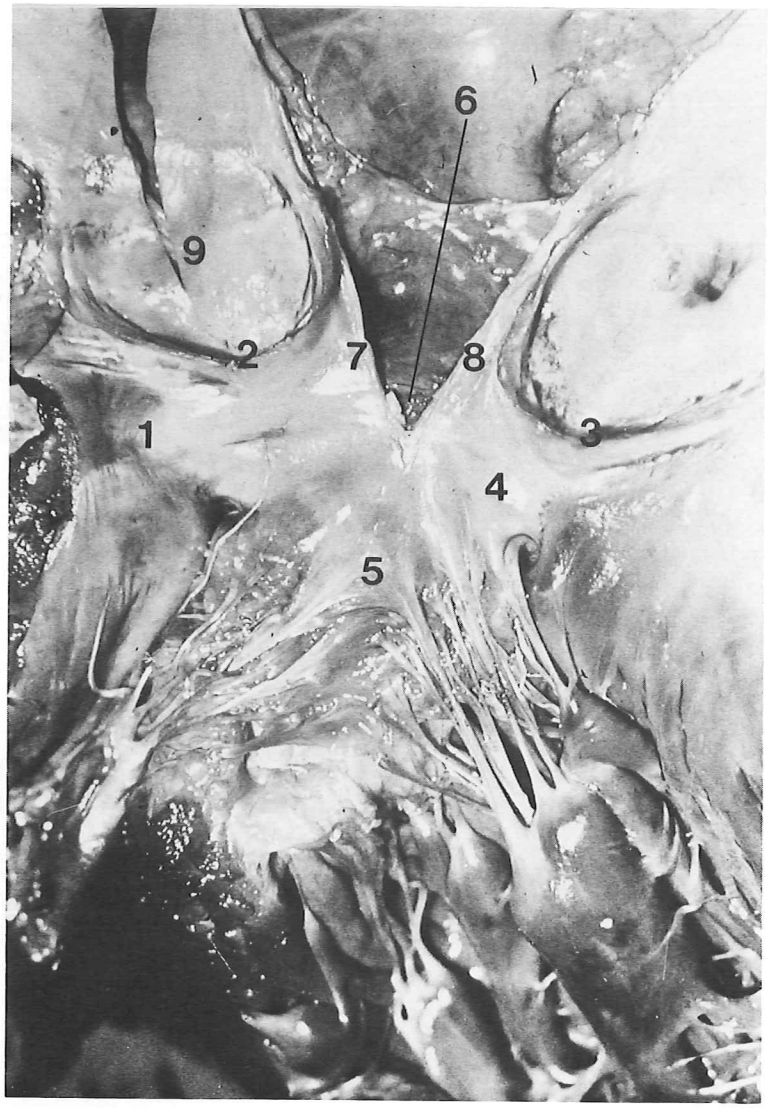

Fig. 2. This anatomic picture shows the topographic relations between the posterolateral part of the aortic root and the anterior mitral leaflet seen from the left ventricle. The septum membranaceum *(1)*, origin of the noncoronary *(2)* and left semilunar *(3)* valves, nonappositional *(4)* and appositional *(5)* portions of the anterior mitral leaflet, and the incision used in this technique are visible. The aortotomy is extended through the intervalvular trigone toward the center of the fibrous origin of the anterior mitral leaflet and in the same direction into the initial portion of this leaflet. In this case the attachment of the left atrial wall *(6)* at the aortic root remains intact. The enlargement of the aortic valve ring *(7-8)* is more than 10 mm. In the noncoronary sinus the incision for an enlargement of the aortic valve ring as described by Nicks and associates[12] is also visible *(9)*.

Operative technique (Fig. 1)

A transverse aortotomy is made into the commissure between the left and the noncoronary cusps. The aortic root and anterior mitral leaflet are retracted carefully with two 5-0 Prolene strings fastened to this commissure. The aortic incision is then extended through the intervalvular trigone toward the center of the fibrous origin of the anterior mitral leaflet and in the same direction into this leaflet (Fig. 1, *a*). The extension of the aortic incision of about 1 cm into the initial portion of the anterior mitral leaflet allows an enlargement of the aortic valve ring of 15 mm. In this case, a lentil-sized aperture at the attachment of the left atrial wall to the aortic root often results. By way of enlarging the

Table I. *Age, previous operation, and intraoperative diagnosis*

Case No.	*Age (yr)*	*Sex*	*Previous operation*	*Intraoperative diagnosis*
1	42	M	Aortic valve replacement (Sept., 1975) with Björk-Shiley No. 23 prosthesis	Paravalvular leak
2	16	M	–	Congenital aortic stenosis
3	8	M	Commissurotomy for congenital aortic stenosis (Sept., 1973)	Residual aortic stenosis, mitral insufficiency
4	16	M	Commissurotomy for congenital aortic stenosis (March, 1969)	Residual aortic stenosis
5	29	F	–	Calcified aortic lesion, asymmetric septal hypertrophy
6	50	F	–	Calcified aortic lesion
7	14	M	–	Acute aortic insufficiency caused by staphylococcal endocarditis
8	40	M	–	Aortic stenosis

aortic valve ring further, the aortotomy is extended far into the anterior mitral leaflet, maximally to its appositional portion. By means of this incision the atrial attachment at the base of the aorta is divided, and the left atrium is entered. The incision in the left atrial wall at the aortic root is then extended superiorly in order to heighten surgical accessibility. A fusiform Dacron or pericardial patch is sutured to the V-shaped defect in the anterior mitral leaflet and in the aortic root with running suture lines (Fig. 1, *b*). Thus continuity between the anterior mitral leaflet and the aorta is reestablished. The resulting enlargement of the aortic anulus allows the implantation of an aortic valve prosthesis whose circumference is larger than the original aortic valve ring (Fig. 1, *c*). Should the aortic incision extend into the initial portion of the anterior mitral leaflet, the aperture at the attachment of the left atrial wall to the aortic root can be closed simply by including the cut edges of the atrium in the running suture lines with which the patch is sutured to the defect in the aortic leaflet of the mitral valve (Fig. 1, *d*). After valve replacement, the free sewing ring of the prosthesis is sewn to the patch with continuous sutures. If the aortic incision extends far into the anterior mitral leaflet, the defect between the left atrial wall and the patch must be closed with continuous sutures or with mattress sutures which also fix the sewing ring of the aortic prosthesis (Fig. 1, *e* and *f*).

Fig. 2 shows the topographic relations between the posterolateral part of the aortic root and the anterior mitral leaflet, seen from the left ventricle. The line of incision of this surgical procedure is visible. The aortic incision is extended through the intervalvular trigone toward the center of the fibrous origin of the anterior mitral leaflet and in the same direction into the initial portion of this leaflet.

Patients and results

Between June, 1976, and February, 1978, eight patients underwent patch enlargement of the aortic valve ring as described previously. The first five patients were operated upon at the Department of Thoracic and Cardiovascular Surgery of Göttingen University, and the other three underwent operation at the Department of Thoracic and Cardiovascular Surgery of Tübingen University. At the time of operation, the patients were between 8 and 50 years old. Their ages, previous operations, and intraoperative diagnosis are summarized in Table I.

The myocardium was protected by intermittent coronary perfusion (Cases 1 and 5), by infusion cardioplegia as described by Bretschneider and colleagues[9] (Cases 2, 3, and 4), and by injection cardioplegia as described by Kirsch and associates[10] (Cases 6, 7, and 8).

The aortic incision was extended by about 1 cm into the initial portion of the mitral valve leaflet in four cases (3, 5, 6, and 8) and far into this leaflet in the other four cases (1, 2, 4, and 7). In two cases (1 and 4) pericardial patches were used for enlargement and in the other cases, Dacron patches. The enlargement of the aortic valve ring ranged from 10 to 25 mm. Figs. 3 and 4 show the patch enlargement of the aortic leaflet of the mitral valve and the aortic valve replacement with a Björk-Shiley No. 27 prosthesis after enlargement of the aortic anulus in Case 1. In five cases (1, 2, 3, 6, and 8) the patient's hospital course was uneventful.

One patient (Case 5) died of myocardial necrosis on the first postoperative day because of insufficient myocardial protection during the operation. Because of the very small coronary ostium, only the smallest available coronary cannula could be inserted into the left coronary artery. After defibrillation the heart did not take

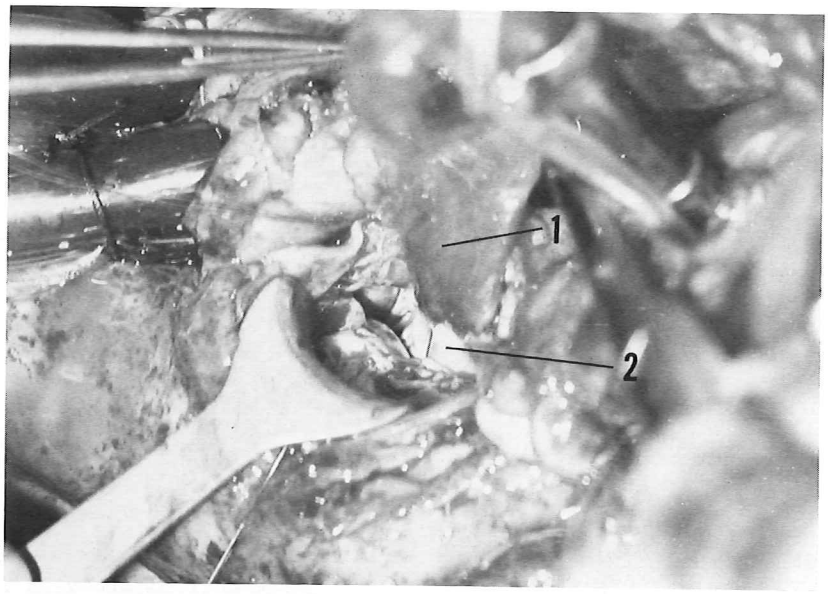

Fig. 3. Case 1. Operative photograph showing the pericardial patch *(1)* which has been sewn into the anterior mitral leaflet *(2)* with continuous sutures.

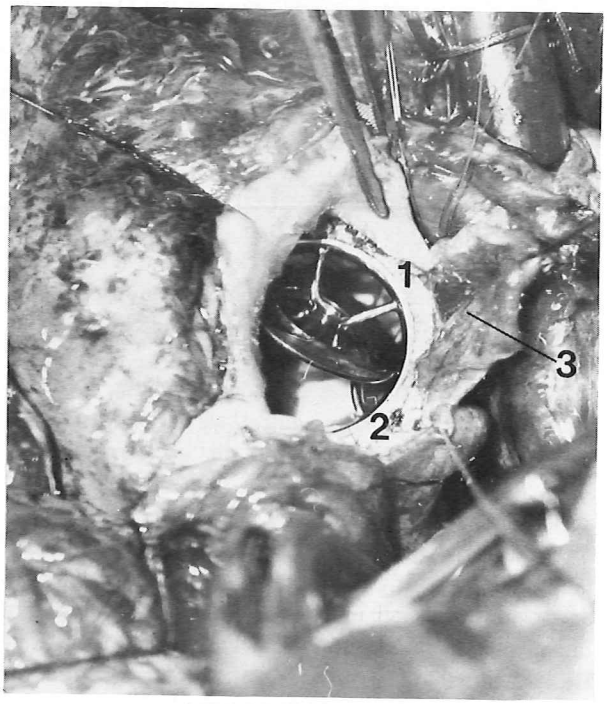

Fig. 4. Case 1. Aortic valve replacement with a Björk-Shiley No. 27 prosthesis. The enlargement of the aortic valve ring *(1-2)* is visible. *3,* Pericardial patch.

over the circulation, and in addition there were signs of mitral insufficiency without an apparent iatrogenic cause. Mitral valve replacement was performed with a Hancock No. 27 prosthesis, without excising the mitral leaflets, to improve hemodynamics and to correct a possibly undiagnosed mitral incompetence caused by asymmetric septal hypertrophy. Postmortem examination showed several large areas of fresh myocardial necrosis in the anterior left ventricular wall, in addition to severe left ventricular hypertrophy. After removal of the Hancock valve, good coaptation of the anterior and posterior mitral leaflets could be demonstrated. All operative sutures were sufficient. There was no sign of coronary injury.

In one patient (Case 4) the pericardial patch broke from the aortic leaflet of the mitral valve (Fig. 5) and caused acute mitral incompetence, so that the mitral valve had to be replaced on the fourth postoperative day. In the area of enlargement of the mitral valve ring at the origin of the anterior mitral leaflet, the sutures were inserted at the base of the shortened pericardial patch and at the sewing ring of the aortic valve prosthesis (Fig. 6). Fig. 7 shows the topographic relations of the aortic and mitral valve prostheses to each other. To our knowledge, enlargement of the aortic and mitral valve rings with replacement of both valves has not previously been described.* This case will be published separately.

*The operative technique of enlargement of the aortic and mitral valve ring with replacement of both valves was developed by one of us (S. M.) in 1976 and 1977 at the Department of Thoracic and Cardiovascular Surgery (Director: Prof. Dr. med. J. Koncz), Georg-August-University, Göttingen, West Germany. The initial results already have been reported.[11]

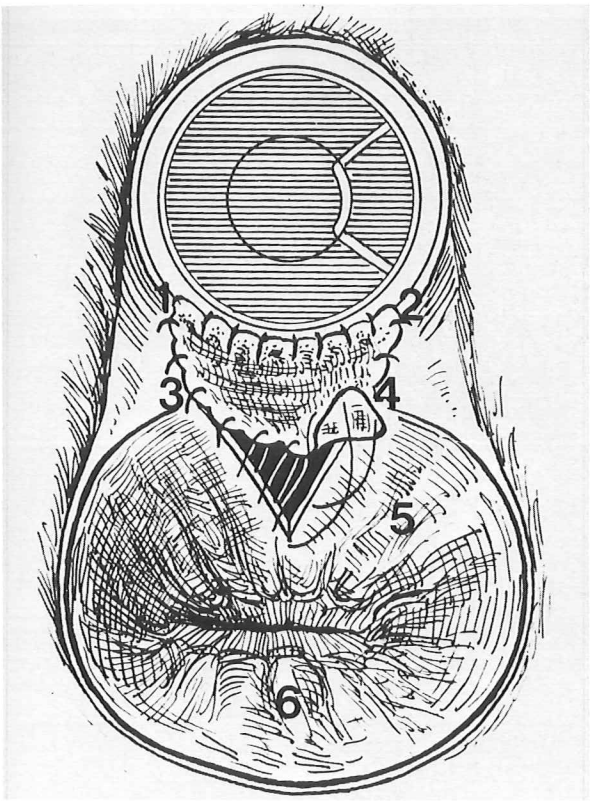

Fig. 5. Case 4. Diagram showing the pericardial patch that broke from the aortic leaflet and caused acute mitral insufficiency. The anatomic conditions are seen from the left atrium after excision of the left atrial wall. In order to make this diagram clearer, the anatomic angle between the aortic root and the mitral ostium is not shown. The enlargement of the aortic *(1-2)* and mitral *(3-4)* valve rings is visible. *5,* Anterior mitral leaflet. *6,* Posterior mitral leaflet.

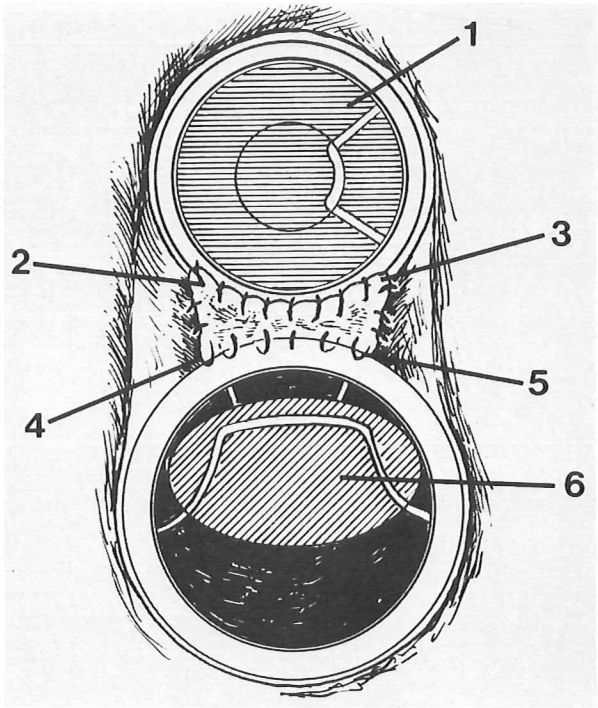

Fig. 6. Case 4. Diagram showing mitral valve replacement after enlargement of the aortic valve ring as described in this study. The anatomic conditions are seen from the left atrium after excision of the left atrial wall. In the area of enlargement of the mitral valve ring, at the origin of the anterior mitral leaflet, sutures are placed at the base of the shortened pericardial patch and at the sewing ring of the aortic valve prosthesis. In order to make this diagram clearer, the anatomic angle between the aortic root and the mitral ostium is not shown. *1,* Aortic valve prosthesis. The enlargement of the aortic *(2-3)* and mitral *(4-5)* valve rings is visible. *6,* Mitral valve prosthesis.

The child who had acute aortic insufficiency along with staphylococcal endocarditis and congestive heart failure (Case 7) died of septicemia 3 months postoperatively. Hemodynamically, the postoperative course was without complication and mitral incompetence was not detectable. Postmortem examination showed an abscess in the septum membranaceum which had perforated from the left ventricle into the right atrium. The Dacron patch had grown firmly into the anterior mitral leaflet. No paravalvular leak was found.

Six to 27 months following operation the clinical condition of six patients (Cases 1, 2, 3, 4, 6, and 8) is good. Figs. 8 and 9 show chest roentgenograms before and 27 months after patch enlargement and aortic valve replacement with a Björk-Shiley No. 27 prosthesis in Case 1.

In Cases 1, 2, 6, and 8, no clinical sign of mitral insufficiency occurred for, respectively, 27, 26, 6, and 6 months following operation. In these cases echocardiography performed after these time intervals showed a normal motility pattern of the anterior mitral leaflet (Fig. 10). In Cases 1 and 2 (11 and 14 months following operation, respectively) cineangiography of the left ventricle after transseptal puncture showed minimal, inconstant regurgitation into the left atrium. Left atrial pressure was normal for both patients. Heart catheterization with cineangiography of the left ventricle is planned for two patients (Cases 6 and 8).

In Case 3, preoperatively diagnosed mitral insufficiency persists. A second-degree apical systolic murmur is audible. Heart catheterization 7 months postoperatively showed the mean left atrial pressure to be 10 mm Hg with a V wave of 22 mm Hg. Comparison of preoperative and postoperative values was not

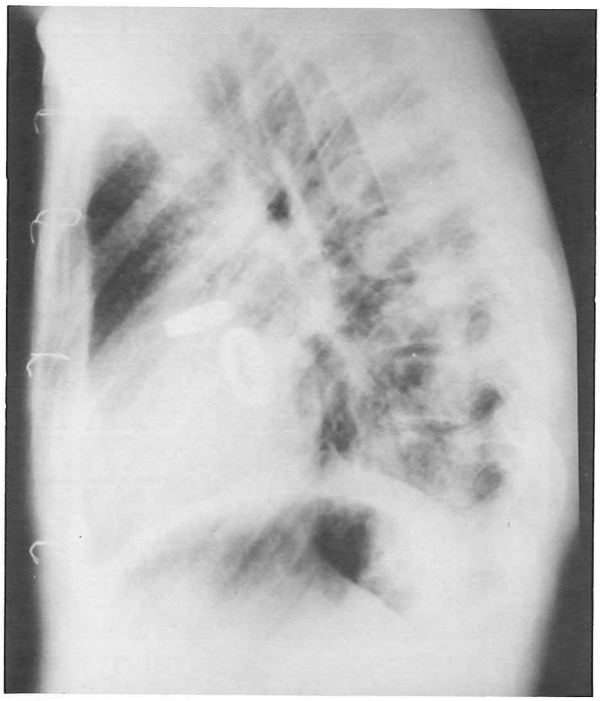

Fig. 7. Case 4. Chest roentgenogram showing the topographic relations of the aortic and mitral valve prostheses to each other.

possible, since there had been no pressure tracing in the left atrium before patch enlargement. In this case echocardiography 18 months postoperatively also showed normal motion of the anterior mitral leaflet.

Simultaneous pressure tracings in the left ventricle and in the ascending aorta gave no significant pressure gradient in Cases 1 and 3. In Case 2 the systolic pressure gradient across the Björk-Shiley No. 23 prosthesis was 30 mm Hg.

Table II shows operative techniques, complications, and results.

Discussion

By the technique of enlargement of the aortic valve ring as described by Nicks,[12] Blank,[13] and their coworkers, the aortic incision is continued downward into the noncoronary sinus, dividing the aortic anulus, and is extended only as far as the origin of the anterior mitral leaflet. The aortic valve ring is usually widened a few millimeters. It is mainly the supravalvular region which is enlarged. Implantation of a prosthesis one size larger than the natural aortic valve ring thereby becomes possible.

Rastan and Koncz,[14] Konno's group,[15] and Sohma and Inoue[16] described the enlargement of the left ventricular outflow tract and of the aortic anulus by a plastic procedure on the ventricular septum. This procedure requires the opening and enlarging of the right ventricular outflow tract as well as the repair of the resulting septal defect. Injuries of important septal arteries and of

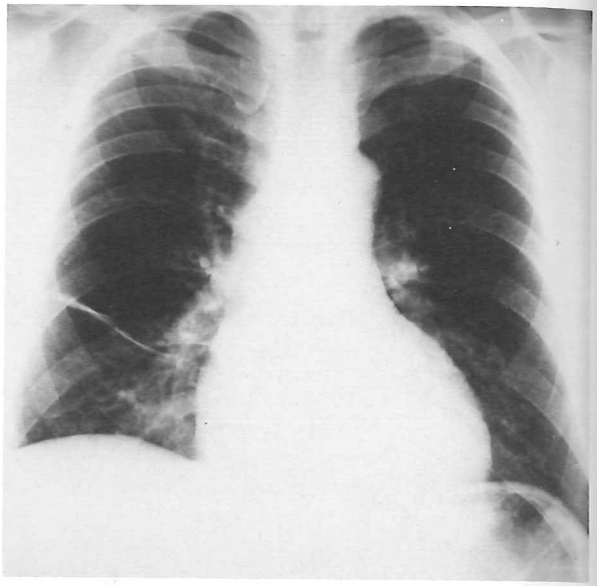

Fig. 8. Case 1. Chest roentgenogram before patch enlargement (aortic insufficiency caused by paravalvular leak).

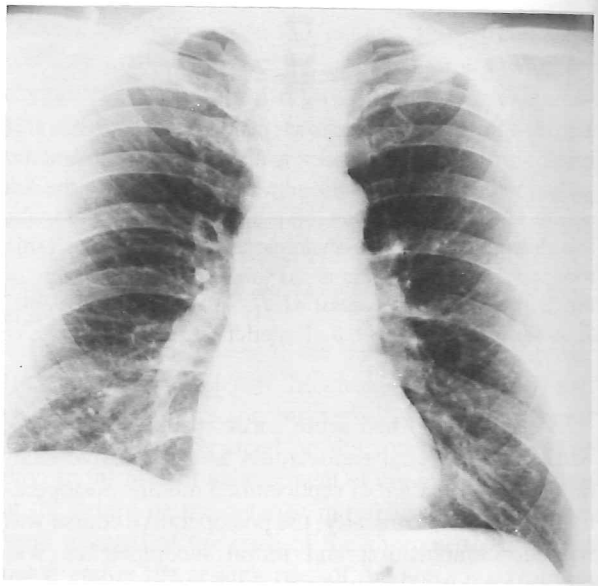

Fig. 9. Case 1. Chest roentgenogram 27 months after patch enlargement and aortic valve replacement with a Björk-Shiley No. 27 prosthesis. The heart is of normal size.

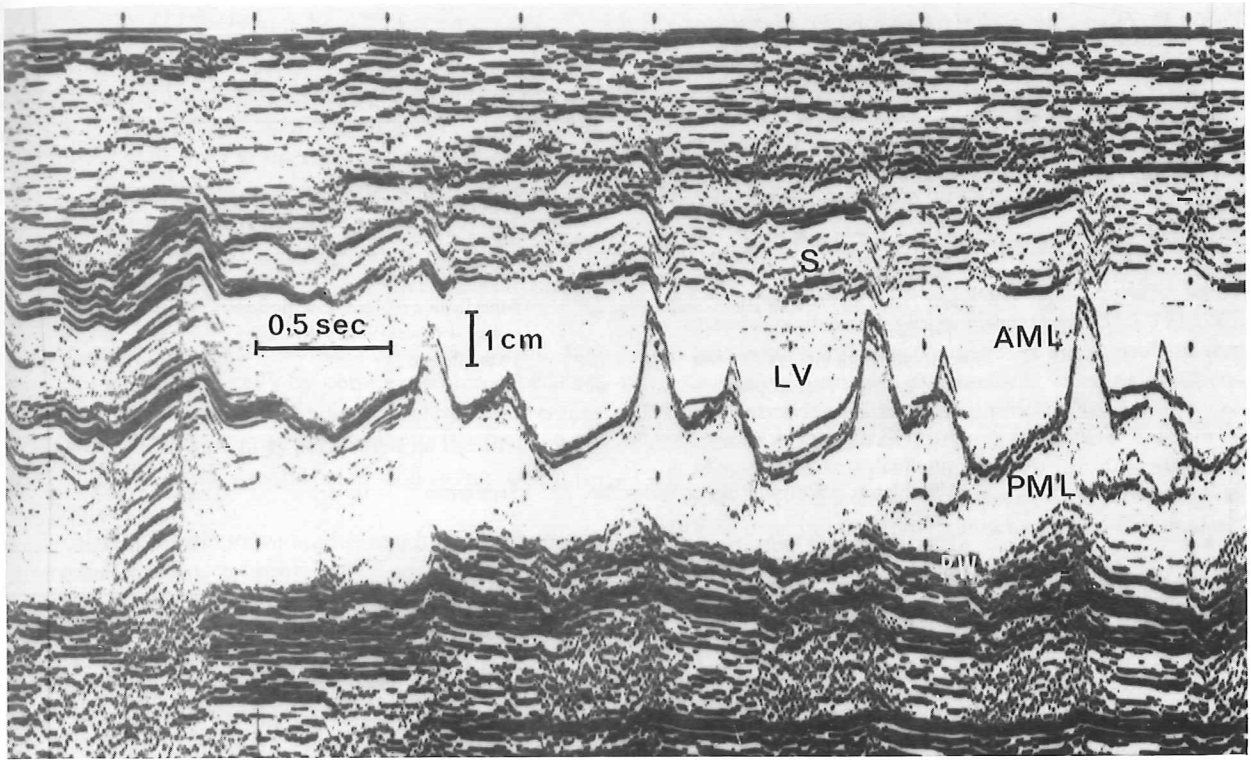

Fig. 10. Case 2. Echocardiogram 26 months postoperatively. Normal motility pattern of the anterior mitral leaflet. *S*, Septum. *LV*, Left ventricle. *AML*, Anterior mitral leaflet. *PML*, Posterior mitral leaflet. *PW*, Posterior wall.

the conducting system (e.g., left hemiblock, complete atrioventricular block) may occur with this technique.[17, 18] The hemodynamic results of aortoventriculoplasty are considered to be good,[17]

Bernhard,[19] Cooley,[20] McGoon,[21] and their associates used a conduit between the left ventricle and, respectively, the thoracic, abdominal, and ascending aorta to relieve congenital obstruction in the left ventricular outflow tract. The hemodynamic results after creation of a double-outlet left ventricle are good.[22] The prognosis of this method is dependent on the durability of the valved conduit.

Application of the special operative technique we[8, 23] describe, here and elsewhere, is appropriate when normal anatomic conditions between the mitral valve and the aortic root obtain. Precise surgical incision is necessary: When the aortic incision is being extended through the intervalvular trigone, it is very important that the incision be directed precisely toward the center of the fibrous origin of the anterior mitral leaflet and in the same direction into it (Fig. 2). In this manner distortions owing to the patch enlargement of the anterior mitral leaflet can be avoided. The incision in this method is located more medially than that described by Nicks,[12] Blank,[13] and their co-workers and consequently is executed more easily. This surgical procedure entails no risk of damaging the conducting system, the main coronary arteries, or their important trunks. The enlargement of the aortic anulus is determined by the extension of the aortic incision into the aortic leaflet of the mitral valve maximally to its appositional portion. The dimensions of the anterior mitral leaflet[24] (width of its origin at the left fibrous anulus, height of its nonappositional portion) make a safe incision possible. The anterior mitral leaflet consists of collagenous fibers and is quite strong and resistant.[6] Patch repair of the aortic leaflet of the mitral valve is thus possible without particular technical difficulty. Access to surgical bleeding at the attachment of the left atrium to the base of the aorta is not readily available while the heart is beating, whereas during cardiac arrest surgical bleeding can be avoided by precise suture technique. To the present date no bleeding complications have occurred in our patients. In cases in which previous operations

Table II. *Operative techniques, complications, and results*

Case No.	*Original valve diameter (mm)*	*Operative procedures*	*Complications*	*Results*
1	22-23	AVR (July, 1976) with Björk-Shiley No. 27 prosthesis	–	Alive and well, no mitral dysfunction
2	17-18	AVR (Oct., 1976) with Björk-Shiley No. 23 prosthesis	Endocarditis (April, 1977)	Alive and well, no mitral dysfunction
3	20-21	AVR (Dec., 1976) with Björk-Shiley No. 25 prosthesis	–	Alive and well, persisting mitral insuff.
4	15-16	AVR (Jan., 1977) with Björk-Shiley No. 23 prosthesis	Mitral valve replacement, postop. day 4 (Björk-Shiley No. 27)	Alive and well
5	17-18	Ventriculomyotomy, AVR with Björk-Shiley No. 23 prosthesis; MVR with Hancock valve, No. 27 (April, 1977)	Heart failure	Died on postop. day 1
6	20-21	AVR (Fb., 1978) with Björk-Shiley No. 25 prosthesis	–	Alive and well, no mitral dysfunction
7	19-20	AVR (March, 1978) with Björk-Shiley No. 25 prosthesis	Septicemia	Died 3 mo postop., no mitral dysfunction
8	24-25	AVR (March, 1978) with Hancock valve, No. 27	–	Alive and well, no mitral dysfunction

Legend: AVR, Aortic valve replacement. MVR, Mitral valve replacement.

had been performed (Cases 1, 3, and 4), the angle between the aortic root and the left atrial wall could be exposed without difficulty.

This surgical technique allows simultaneous enlargement of the aortic and mitral valve rings at the origin of the anterior mitral leaflet. Patching this leaflet permits an enlargement of the left ventricular outflow tract. Furthermore, the enlargement of the ascending aorta is achieved by patching the aorta above the valve ring.

It has been thought that enlargement of the mitral valve ring at the origin of the anterior mitral leaflet by patching this leaflet is apt to cause mitral insufficiency. However, this assumption can be refuted by the following findings concerning the functional anatomy of the mitral valve:

1. Unlike the posterior leaflet, the origin of the anterior mitral leaflet in the section of the left fibrous anulus between the left and right fibrous trigone is not folded or stretched during heart action.[5]

2. Unlike the posterior leaflet, during systole and diastole, the anterior mitral leaflet is pressed against the posterior leaflet and is opened only mechanically by external factors.[6]

3. During systole, the nonappositional portion of the anterior leaflet meets the appositional portion at a right angle,[4] and a greater proportion of the posterior leaflet is in apposition to the anterior leaflet.[24]

With the present surgical technique, four patients showed no impairment of mitral valve function 6 to 27 months after operation. One child died of septicemia 3 months postoperatively; mitral insufficiency was not detectable. In one case the preoperatively diagnosed mitral insufficiency persists. Acute insufficiency of the mitral valve in Case 4 resulted after the pericardial patch broke from the anterior mitral leaflet. This is a possible complication of this technique. Resultant mitral insufficiency can be treated by renewed patch repair of the aperture in the mitral leaflet. In case of this complication, mitral valve replacement may also be considered, as was accomplished in Case 4. At reoperation, access must be sought through the left atrium. In Case 5 sufficient myocardial protection could not be obtained, and functional mitral insufficiency caused by left heart failure ensued. Postmortem examination showed several large areas of fresh necrosis of the left ventricle. In such a patient, cardioplegia should be used for myocardial protection.[9, 10]

There is no permanent impairment of mitral function when the extension of the aortic incision into the anterior mitral leaflet is limited to about 1 cm, because the initial portion of the anterior mitral leaflet is not actively involved in valve action.[5, 6] However, if the aortic incision were to be extended into the appositional portion of the anterior mitral leaflet, the possibility of subsequent functional impairment of the mitral valve due to patch shrinking, stiffening, or to distortion of the anterior mitral leaflet cannot presently be excluded. All we can say is that in two cases (Cases 1 and 2) in which the aortic incision was extended far into the mitral leaflet, no impairment of mitral valve function (e.g., insufficiency, paradoxical motility of the anterior mitral

leaflet) was found 27 and 26 months after patch enlargement, respectively. Mitral valve dysfunction resulting from this surgical technique would necessitate mitral valve replacement. In the area of enlargement of the mitral valve ring at the origin of the anterior mitral leaflet, sutures would have to be made at the base of the shortened patch and, if necessary, at the sewing ring of the aortic valve prosthesis (Fig. 6).

In our opinion indications for this method are as follows:

1. Congenital aortic stenosis that cannot be improved hemodynamically by commissurotomy because of unfavorable anatomic findings. Patch enlargement with valve replacement is performed as the first operative step or as a second step following commissurotomy.

2. Narrow aortic valve anulus in adults (aortic valve diameter less than 21 mm).

3. Aortic valve replacement in a growing child without a hypoplastic anulus. Our operative technique permits the implantation of a sufficiently large valve prosthesis and avoids later reoperation.

4. Implantation of a larger aortic valve prosthesis in patients who have undergone valve replacement during childhood and whose prostheses no longer satisfy the hemodynamic needs of the adult.

Possible deterioration of the function of an incompetent mitral valve after patch enlargement, as described here, cannot be excluded. We thus believe that this technique is contraindicated in cases of relative mitral incompetence that do not necessitate immediate valve replacement. Because of the risk of surgical bleeding, a calcified aortic aortico-mitral septum and anterior mitral leaflet also contraindicate this method.

Addendum

At the Heart Center, Queen Pahlavi Foundation, Teheran, Iran, two patients were operated upon by the technique described above. They are reported in reference 23. Since the completion of this manuscript, six additional patients have been operated upon by this method in Tübingen by Dr. Seybold-Epting. There were no complications owing to this method.

REFERENCES

1 Björk VO, Henze A, Holmgren A, et al: Evaluation of the 21 mm Björk-Shiley tilting disc valve in patients with narrow aortic roots. Scand J Thorac Cardiovasc Surg **7:** 203-213, 1973

2 Huhmann W, Dalichau H, Lichtlen P, Borst HG: Zur Funktionsfähigkeit der Lillehei-Kaster-Klappe in Aortenposition. Thoraxchirurgie **24:**390-396, 1976

3 Morris DC, Wickliffe CW, King SB, et al: Hemodynamic evaluation of the porcine xenograft aortic valve. Am J Cardiol **37:**157, 1976

4 McAlpine WA: Heart and Coronary Artery. Heidelberg, New York, Berlin, 1975, Springer Verlag, p 52

5 Puff A: Über das funktionelle Verhalten des Anulus fibrosus bei der Volumenänderung der Herzhöhlen und die Konsequenzen für einen Klappenersatz. Thoraxchirurgie **20:**185-198, 1972

6 Puff A: Funktionelle Anatomie des Herzklappenapparates. Verh Dtsch Ges Kreislaufforsch **31:**1-15, 1965

7 Manouguian S: Erweiterungsplastik des hypoplastischen Aortenklappenringes. Beschreibung einer neuen Operationsmethode. Eine experimentelle Studie. Thoraxchirurgie **24:**418-423, 1976

8 Manouguian S: Erweiterungsplastik des Aortenklappenringes. Beschreibung einer neuen Operationsmethode. Eine experimentelle und klinische Studie. Habilitationsschrift Göttingen, 1977

9 Bretschneider HJ, Hübner G, Knoll D, Lohr B, Nordbeck H, Spieckermann PG: Myocardial resistance and tolerance to ischemia. Physiological and biochemical basis. J Cardiovasc Surg **16:**241-260, 1975

10 Kirsch U, Rodewald G, Kalmar P: Induced ischemic arrest. Clinical experience with cardioplegia in open-heart surgery. J THORAC CARDIOVASC SURG **63:**121-130, 1972

11 Manouguian S, Rastan H, Abu-Aishah N, Kirchhoff PG: Erweiterungsplastik des Mitralklappenringes. Eine experimentelle Studie. Acta Chir Aust Sondersupplement 1977/1978, pp 890-896

12 Nicks R, Cartmill T, Bernstein L: Hypoplasia of the aortic root. Thorax **25:**339-346, 1970

13 Blank RH, Pupello DF, Bessone LN, Harrison EE, Sbar S: Method of managing the small aortic annulus during valve replacement. Ann Thorac Surg **22:**356-361, 1976

14 Rastan H, Koncz J: Plastische Erweiterung der Ausflußbahn der linken Kammer. Eine neue Operationsmethode. Thoraxchirurgie **23:**169-175, 1975

15 Konno S, Imai Y, Nakajima M, Fida Y: A new method for prosthetic valve replacement in congenital aortic stenosis associated with hypoplasia of the aortic valve ring. Bull Heart Inst Jpn **15:**1-17, 1974

16 Sohma Y, Inoue T: Right coronary cusp approach. Patch enlargement of narrow aortic annulus and aortic valve replacement. Jpn J Thorac Surg **28:**41-47, 1975

17 Rastan H, Abu-Aishah N, Rastan D, Heisig B, Koncz J, Björnstad PG, Beuren AJ: Results of aortoventriculoplasty in 21 consecutive patients with left ventricular outflow tract obstruction. J THORAC CARDIOVASC SURG **75:**659-669, 1978

18 Abu-Aishah N: Discussion of Rastan et al[17]

19 Bernhard WF, Poirier V. LaFarge CG: Relief of congenital obstruction to left ventricular outflow with a ventricular-aortic prostheses. J THORAC CARDIOVASC SURG **69:**223-229, 1975

20 Cooley DA, Norman JC, Mullins CE, Grace RR: Left

ventricule to abdominal aorta conduit for relief of aortic stenosis. Bull Texas Heart Inst **2:**376-383, 1975

21 McGoon DC: Left ventricular and biventricular extracardiac conduits. J THORAC CARDIOVASC SURG **72:**7-14, 1976

22 Norman JC, Cooley DA, Hallman GL, Nihill MR: Left ventricular apical–abdominal aortic conduits for left ventricular outflow tract obstructions. Clinical results in nine patients with a special composite prosthesis. Circulation **54:**Suppl 2:100, 1976

23 Manouguian S, Rastan H, Abu-Aishah N, Kirchhoff PG, Koncz J: A new method for patch enlargement of hypoplastic aortic anulus. Proceedings International Congress of Cardiovascular Surgery, Athens, 1977, pp 94-99

24 Ranganathan N, Lam JHC, Wigle ED, Silver MD: Morphology of the human mitral valve. II. The valve leaflets. Circulation **41:**459-467, 1970

Information for authors

Most of the provisions of the Copyright Act of 1976 became effective on January 1, 1978. Therefore, all manuscripts must be accompanied by the following written statement, signed by one author: "The undersigned author transfers all copyright ownership of the manuscript (title of article) to The C. V. Mosby Company in the event the work is published. The undersigned author warrants that the article is original, is not under consideration by another journal, and has not been previously published. I sign for and accept responsibility for releasing this material on behalf of any and all co-authors." Authors will be consulted, when possible, regarding republication of their material.